

ONLINE FIRST

An Internally Controlled, Double-blind Comparison of the Efficacy of OnabotulinumtoxinA and AbobotulinumtoxinA

Kartik D. Nettar, MD; Kenneth C. Y. Yu, MD; Sumit Bapna, MD; John Boscardin, PhD; Corey S. Maas, MD

Objective: To compare 2 commercially available botulinum neuromodulators in a randomized, double-blind, split-face study.

Methods: Ninety patients were treated with 10 U of onabotulinumtoxinA and 30 U of abobotulinumtoxinA for the treatment of lateral orbital rhytids. Patients were assessed live with a validated 5-point photographic scale prior to treatment and at 30 days. Patients were also photographed at each visit.

Results: AbobotulinumtoxinA demonstrated a statistically significant advantage compared with onabotulinumtoxinA in the treatment of lateral orbital rhytids at maximal contraction, as evaluated independently by the investigator ($P = .01$) and patient ($P = .03$). Abobotu-

linumtoxinA was also favored by the patient over onabotulinumtoxinA 67% of the time. While abobotulinumtoxinA seemed to treat lateral orbital rhytids better at rest, as evidenced by the data and photographs, this difference was not statistically significant ($P = .42$).

Conclusions: AbobotulinumtoxinA offers superior efficacy in the treatment of lateral orbital rhytids compared with onabotulinumtoxinA. Further studies are needed to compare the 2 products in different muscle groups and for other indications.

Arch Facial Plast Surg.

Published online June 20, 2011.

doi:10.1001/archfacial.2011.37

Author Affiliations: The Maas Clinic (Drs Nettar, Yu, Bapna, and Maas), and Departments of Otolaryngology–Head and Neck Surgery (Drs Nettar, Yu, Bapna, and Maas) and Biostatistics and Medicine (Dr Boscardin), University of California, San Francisco.

BOTULINUM TOXIN, A 149-KD protein produced by the bacterium *Clostridium botulinum*, is a potent neuromodulator, which works at the neuromuscular junction by inhibiting exocytosis of acetylcholine synaptic vesicles. The protein is composed of a heavy chain and a light chain, the latter a metalloproteinase responsible for cleaving a fusion protein responsible for vesicle docking and exocytosis. Although these proteins have been known as toxins, today they are better characterized as neuromodulators owing to their current widespread application in selective relaxation of muscles and muscle groups.

Seven naturally occurring serotypes of botulinum neuromodulator have been identified. However, only the A serotype has demonstrated sustained benefit and efficacy in clinical applications. The B serotype (Myobloc; Solstice Neurosciences, San Francisco, California) did offer favorable results in hyperfunctional frown

lines. However, because of the pain associated with injection and short duration of action, clinical use has been limited.¹

In the 1970s and 1980s, Allen B. Scott, MD, of San Francisco, California, demonstrated relaxation of muscle groups in the treatment of strabismus. The US Food and Drug Administration (FDA) approved botulinum toxin type A for the treatment of strabismus and blepharospasm in 1989.² Thus began clinical applications of the neuromodulator. This led to expanded clinical uses, including muscular relaxation in dystonias, hemifacial spasm, and rhytids.

Beginning in the 1990s and continuing through today, much investigation has been directed at the cosmetic applications of botulinum neuromodulator. In 1992, Carruthers and Carruthers³ in Canada were among the first to report on its use in the treatment of glabellar lines in the plastic surgery literature.⁴ Subsequently, in 2002, the FDA approved Botox Cosmetic (onabotulinumtoxinA) (Allergan Inc, Irvine, California) for the treatment

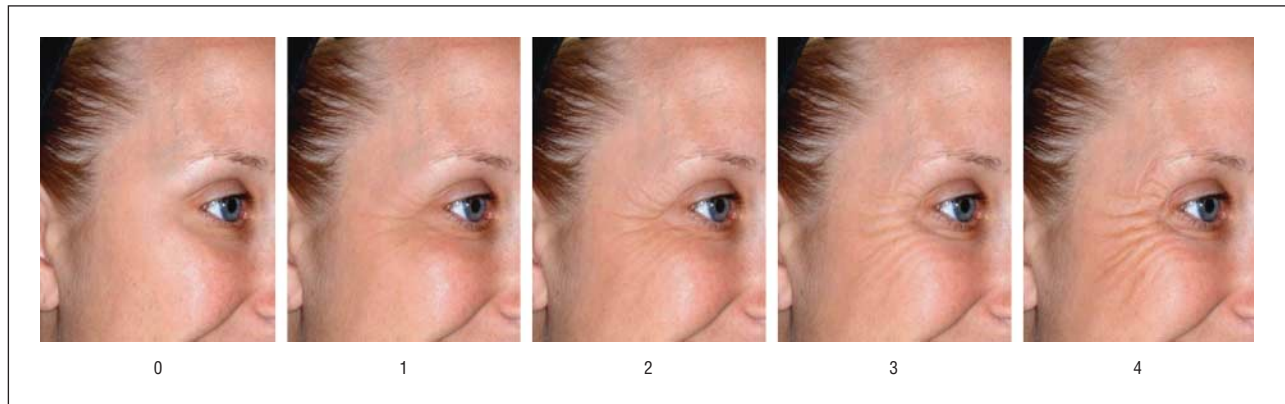

Figure 1. A validated 5-point photographic scale for lateral orbital rhytids. (Reproduced with permission from Merz Aesthetics Inc, Frankfurt, Germany; http://www.merzaesthetics.eu/en/products/merzscapes/crowsfeet/crowsfeet_1.jsp.) 0 Indicates no wrinkles; 1, very fine lines; 2, fine lines; 3, moderate wrinkles; and 4, severe wrinkles.

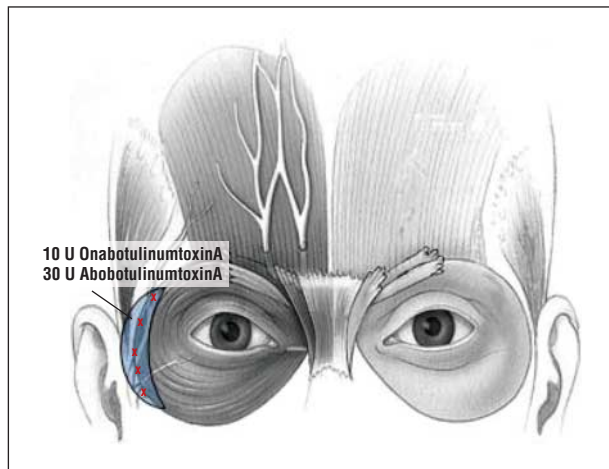


Figure 2. Lateral orbital rhytid treatment injection points.

of corrugator-mediated glabellar lines.⁵ Concurrently, another botulinum toxin type A product manufactured by Medicis Aesthetics (Scottsdale, Arizona), Dysport (abobotulinumtoxinA), had been used in other countries since 1991.⁵ It was approved for cosmetic use in Europe in 2001, before being approved by the FDA in April 2009 for the treatment of moderate-to-severe glabellar lines. Today, the cosmetic applications for onabotulinumtoxinA and abobotulinumtoxinA have expanded to the treatment of hyperfunctional lines related to the orbicularis oculi, frontalis, transverse nasalis, and depressor anguli oris, among other muscle groups.

While onabotulinumtoxinA and abobotulinumtoxinA have been used globally for 9 years and in the United States for nearly 2 years, to date, there have been no double-blind, internally controlled studies comparing the 2 products. Such an assessment could characterize and contrast their efficacy in clinical performance in the treatment of hyperfunctional lines and muscle relaxation. By using a split-face (internally controlled) paradigm, this would provide direct comparison of each product in the same patient. In an effort to minimize and/or eliminate any crossover effect or product diffusion (as would be seen in split-face forehead or glabellar studies), the lateral orbital rhytids (“crow’s feet”) were chosen for study.

METHODS

From December 2009 to August 2010, 90 patients (77 women and 13 men) were enrolled in a randomized, double-blind study. Included in the study were men or women 18 years or older, with moderate to severe lateral orbital rhytids at maximal contraction. Exclusion criteria included botulinum neuromodulator treatment to the crow’s feet within the prior 6 months; prior face-lift, brow-lift, or blepharoplasty; prior periocular laser or chemical resurfacing; and prior adverse reaction associated with botulinum neuromodulator. In addition, patients with a history of degenerative neuromuscular diseases were ineligible to participate in this study. The study design and conduct was approved by an independent institutional review board (Aspire, San Diego, California). Informed consent was obtained from each patient prior to enrollment in the study.

Prior to treatment and during each subsequent follow-up visit, photographs were recorded for each patient using Mirror software (Canfield Scientific Inc, Fairfield, New Jersey) and a Nikon D90 camera (Nikon Inc, Melville, New York) in a dedicated photographic lane. A standard 5-view photographic series was taken for each patient at rest and at maximal contraction. In addition, prior to treatment and at each follow-up visit, the patient and investigator separately assessed lateral orbital rhytids at rest and at maximal contraction on each side, according to a validated 5-point photographic scale⁶ (0, no wrinkles; 1, very fine lines; 2, fine lines; 3, moderate wrinkles; and 4, severe wrinkles) used in previous studies (Merz Scale; Merz Aesthetics Inc, Frankfurt, Germany) (**Figure 1**). A written description of each photograph was included to help standardize the application of the photographic scale.

The treatment consisted of 10 U of onabotulinumtoxinA on one side of the face while the contralateral side received 30 U of abobotulinumtoxinA. This dosage ratio was chosen based on the preponderance of evidence recommending a 3:1 dosage ratio of abobotulinumtoxinA to onabotulinumtoxinA.⁷⁻¹¹ While some studies have even called for higher ratios of 4:1 or 5:1,^{12,13} recent studies and the clinical experience of the senior investigator point to a 3:1 ratio as being optimal.^{7,9-11}

Treatment sides of the face were randomized with computer-aided software. Preparation of product was performed by an unblinded registered nurse who was responsible for maintaining the blind. A 100-U vial of onabotulinumtoxinA was reconstituted with 2.4 mL of 0.9% sterile physiologic saline without preservative, while a 300-U vial of abobotulinumtoxinA was reconstituted with 2.0 mL of 0.9% sterile physiologic saline without preservative. Identical volumes (0.2 mL) of each were drawn into tuberculin syringes to ensure the blindedness of the in-

Table 1. Comparison of Assessment of Baseline Lateral Orbital Rhytid Value Using the Merz Scale^a

Assessor	OnabotulinumtoxinA-Treated Side	AbobotulinumtoxinA-Treated Side
Investigator		
Patient at rest	2.98	2.84
Patient at maximal contraction	3.68	3.64
Patient		
While at rest	2.91	2.86
While at maximal contraction	3.60	3.60

^aMerz Aesthetics Inc, Frankfurt, Germany.

Table 2. Summary Statistics of Investigator Assessment of Efficacy Using the Merz Scale^a

Treatment	Change in Assessment Value, Mean (SD)	
	At Rest	At Maximal Contraction
OnabotulinumtoxinA-treated side	1.69 (0.77)	2.33 (0.79)
AbobotulinumtoxinA-treated side	1.77 (0.83)	2.60 (0.75)
Difference of efficacy	0.08 (0.92)	0.26 (0.95)
<i>P</i> value for <i>t</i> test	.42	.01

^aMerz Aesthetics Inc, Frankfurt, Germany.

jector. A dose of 0.05 mL of onabotulinumtoxinA or abobotulinumtoxinA was injected into the orbicularis oculi in the lateral orbital area in 5 separate injection points (**Figure 2**) by the senior author and principal investigator (C.S.M.).

Patients were then seen and evaluated on posttreatment days 2, 4, 6, and 30. The primary end point of the study was efficacy of action as defined by investigator assessment of maximal contraction at day 30 compared with day 0. Day 30 efficacy was chosen because this interval replicates primary efficacy end points used in the FDA clinical trials for both products. Secondary end points were investigator assessment at rest at day 30 compared with day 0, patient assessment at rest and at maximal contraction at day 30 compared with day 0 and patient preference of each side's result at day 30.

Statistical analyses included the paired *t* test and McNemar test. Efficacy was defined as the amount of improvement at 30 days relative to baseline. A paired Wilcoxon signed rank test was used to compare the differences in efficacy for abobotulinumtoxinA and onabotulinumtoxinA. For the patient preference data, we computed the proportion of patients preferring each of the 2 products and tested whether these differed significantly from each other using a test for the proportion from a single sample of binomial data. The statistical data and analysis were performed by one of us (J.B.).

RESULTS

The mean age of patients in the study was 54.5 years (range, 31-78 years). Ninety patients were recruited for the study after meeting inclusion criteria. Investigator and patient baseline values of lateral orbital rhytid assessment at rest and at maximal contraction are provided in **Table 1**.

Table 3. Summary Statistics of Patient Assessment of Efficacy Using the Merz Scale^a

Treatment	Change in Assessment Value, Mean (SD)	
	At Rest	At Maximal Contraction
OnabotulinumtoxinA-treated side	1.61 (0.91)	2.13 (0.91)
AbobotulinumtoxinA-treated side	1.71 (0.90)	2.34 (0.97)
Difference of efficacy	0.10 (0.89)	0.22 (0.91)
<i>P</i> value for <i>t</i> test	.28	.03

^aMerz Aesthetics Inc, Frankfurt, Germany.

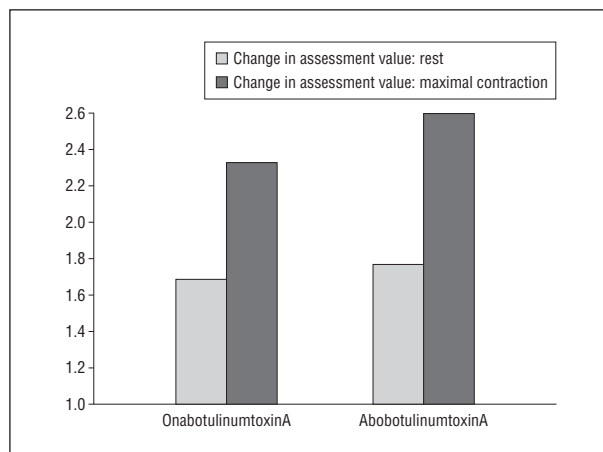


Figure 3. Comparison of change from baseline to day 30 (investigator assessment) using the Merz scale (Merz Aesthetics Inc, Frankfurt, Germany).

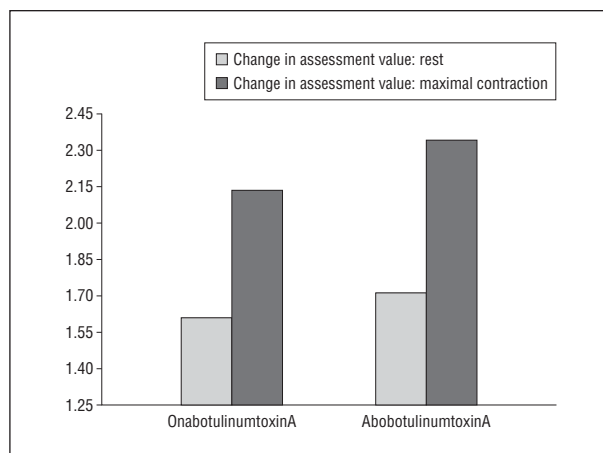


Figure 4. Comparison of change from baseline to day 30 (patient assessment) using the Merz scale (Merz Aesthetics Inc, Frankfurt, Germany).

No major adverse events were reported by any patient with either side of the face. One patient did report bruising at an injection site on the onabotulinumtoxinA-treated side of the face, which resolved within 5 days.

The results indicate an overall statistically significant result in the primary end point and one of the secondary end points (**Table 2** and **Table 3**). This is also illustrated in **Figure 3** and **Figure 4**. Photographic evidence also pointed to a striking difference between the

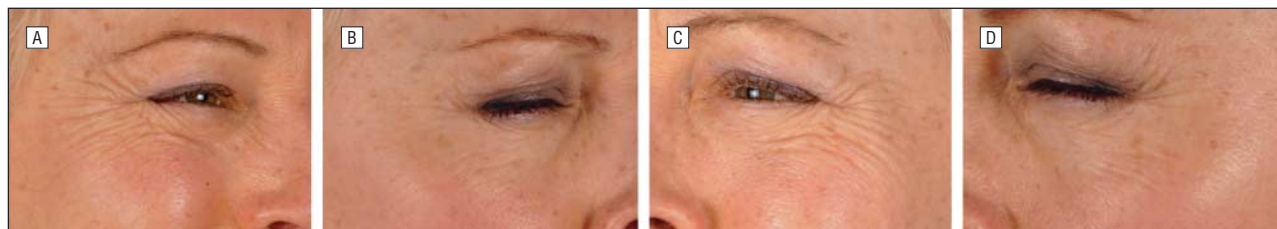

Figure 5. Dynamic photographs of a patient. She was treated with abobotulinumtoxinA on the right side of her face (A and B) and with onabotulinumtoxinA on the left side (C and D). A and C, Day 0; B and D, day 30.

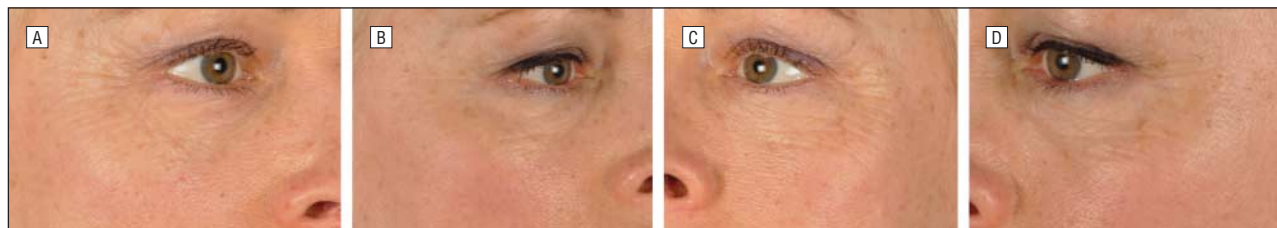

Figure 6. Static photographs of the patient shown in Figure 5. She was treated with abobotulinumtoxinA on the right side of her face (A and B) and with onabotulinumtoxinA on the left side (C and D). A and C, Day 0; B and D, day 30.

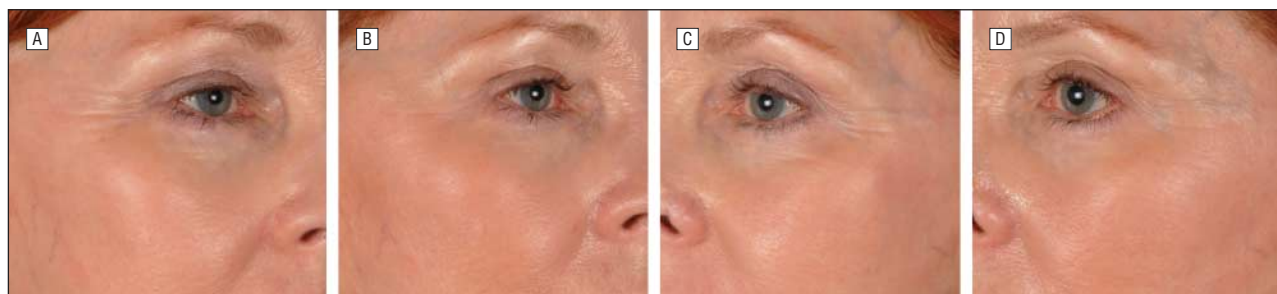


Figure 7. A photograph of a patient at rest. She was treated with abobotulinumtoxinA on the right side of her face (A and B) and with onabotulinumtoxinA on the left side (C and D). A and C, Day 0; B and D, day 30.

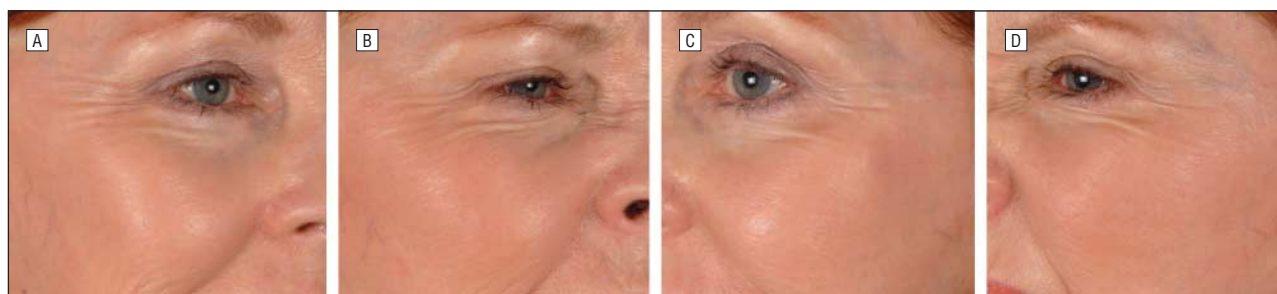


Figure 8. The same patient in Figure 7 showing maximal contraction. Abobotulinumtoxin was used to treat the right side of her face (A and B), and onabotulinumtoxinA was used to treat the left side (C and D). A and C, Day 0; B and D, day 30.

treated sides of each patient's face (**Figures 5, 6, 7, 8, 9, 10, 11, 12, 13, and 14**).

Patient preference of treatment side was also queried at day 30. Patients were asked to indicate which side of their face they thought achieved a better result compared with pre-treatment. Sixty-seven percent of patients preferred the side treated with abobotulinumtoxinA, while 33% of patients chose the side treated with onabotulinumtoxinA. This difference was statistically significant ($P = .002$).

COMMENT

The data revealed that abobotulinumtoxinA offers superior efficacy in the treatment of lateral orbital rhytids com-

pared with onabotulinumtoxinA, based on a 30-day assessment. While the greatest difference was seen in the investigator assessment of maximal contraction—the primary end point—a statistically significant difference was also seen in patient assessment of maximal contraction—a secondary end point. Two other secondary end points, investigator and patient assessments of resting lateral orbital rhytids, did not achieve statistical significance ($P = .42$ and $P = .28$, respectively). Nonetheless, live assessments of each patient and photographic documentation also suggest an advantage in resting lines with abobotulinumtoxinA.

The results also indicated that patients unequivocally preferred the abobotulinumtoxinA-treated side to

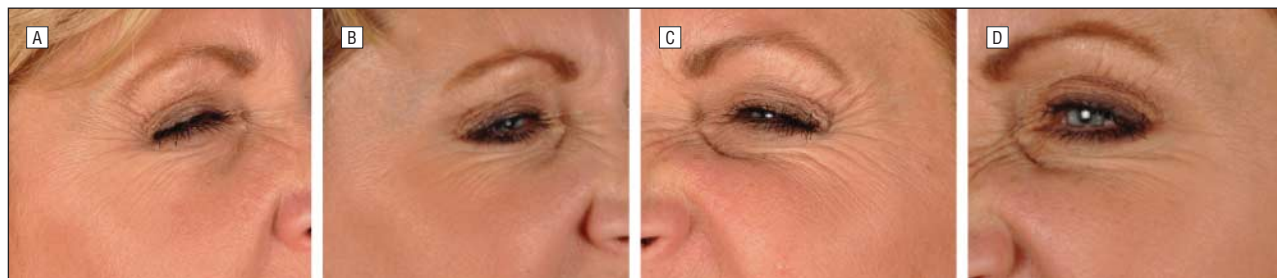

Figure 9. Photographs of a patient. She was treated with abobotulinumtoxinA on the right side of her face (A and B) and with onabotulinumtoxinA on the left side (C and D) at maximal contraction. A and C, Day 0; B and D, day 30.

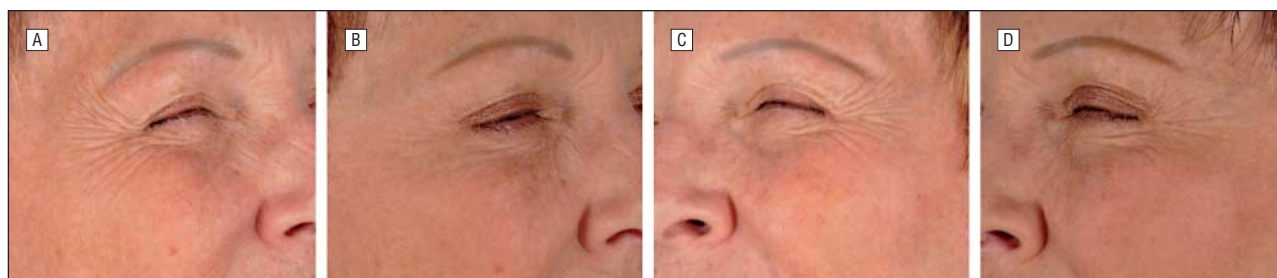

Figure 10. Photographs of a patient. She was treated with abobotulinumtoxinA on the right side of her face (A and B) and onabotulinumtoxinA on the left side (C and D) at maximal contraction. A and C, Day 0; B and D, day 30.

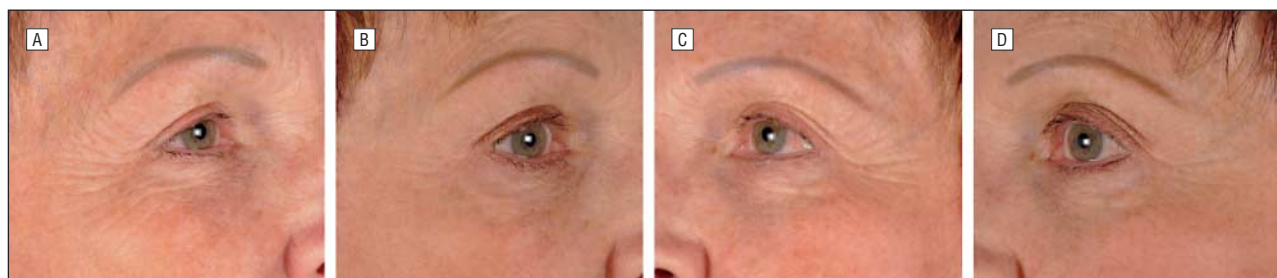

Figure 11. The same patient as in Figure 10. She was treated with abobotulinumtoxinA on the right side of her face (A and B) and onabotulinumtoxinA on the left side (C and D) at rest. A and C, Day 0; B and D, day 30.

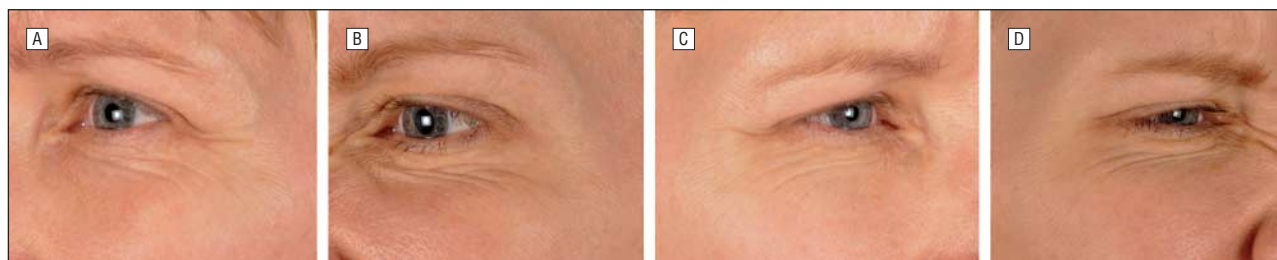


Figure 12. Photographs of a patient. She was treated with onabotulinumtoxinA on the right side of her face (A and B) and abobotulinumtoxinA on the left side (C and D) at maximal contraction. A and C, Day 0; B and D, day 30.

the onabotulinumtoxinA-treated side by a 2:1 ratio. While this was a secondary end point, the χ^2 value clearly achieved statistical significance ($P = .42$). Though this study clearly demonstrates the superior efficacy of abobotulinumtoxinA in the treatment of lateral orbital rhytids, it cannot answer the question of why there is an observable difference. The primary pharmacologic difference between onabotulinumtoxinA and abobotulinumtoxinA is the difference in hemagglutinin and nonhemagglutinin surrounding each protein. Because there is an observable difference between the 2 products, one may

theorize that these differences in efficacy can be ascribed to the hemagglutinin and nonhemagglutinin binding. Further studies are needed to elucidate their role.

Observed differences may also be related to the morphologic mechanisms of the muscle being treated. The orbicularis oculi, a flat, sheetlike muscle, may respond differently to abobotulinumtoxinA compared with the response of a thick, bulky muscle, such as the corrugator supercilii. It is clear from early clinical experience that the area of “smoothing effect” in treating other flat muscle groups with abobotulinumtoxinA, such as the frontalis, shows consid-

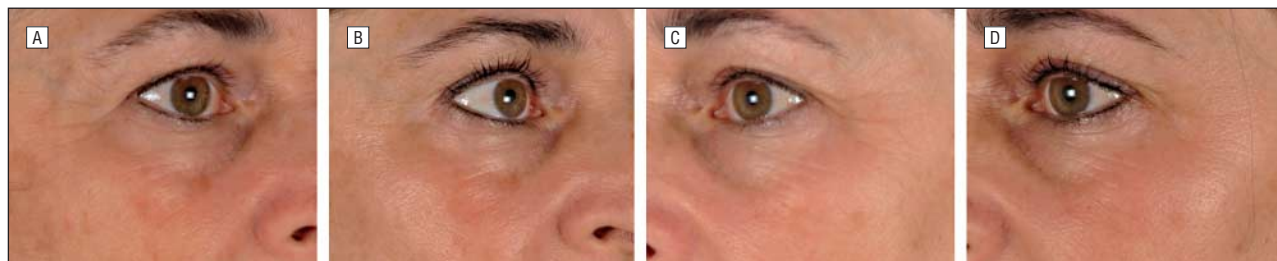


Figure 13. Photographs of a patient. She was treated with abobotulinumtoxinA on the right side of her face (A and B) and onabotulinumtoxinA on the left side of her face (C and D) at rest. A and C, Day 0; B and D, day 30.

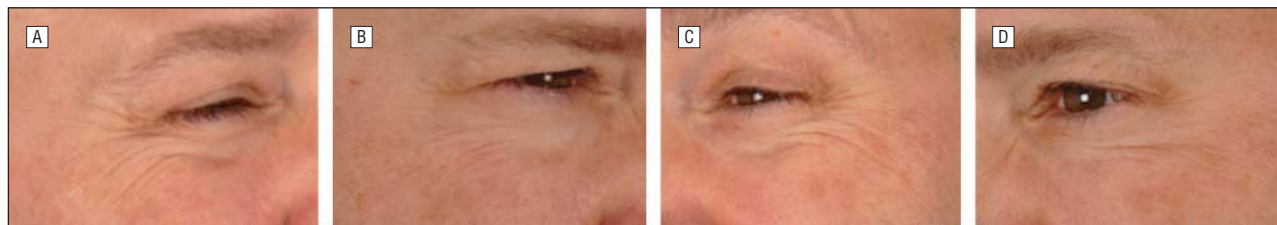

Figure 14. Photographs of a patient. He was treated with abobotulinumtoxinA on the right side of his face (A and B) and onabotulinumtoxinA on the left side (C and D) at maximal contraction. A and C, Day 0; B and D, day 30.

erable effacement of lines and smoothing effect. Comparative studies between the 2 products used in bulkier muscles would help answer this question.

Although the data did not achieve statistical significance for investigator ($P = .42$) or patient ($P = .28$) assessment of lateral orbital rhytids at rest, a clear difference between the 2 treatment sides at rest was observed. The failure to achieve statistical significance may reflect a limitation of the 5-point scale. Visible differences between each side of the face, while perceptible to the patient and trained eye, may not neatly correspond to each point on the 5-point scale. A more subjective global assessment linear analog scale might have been more sensitive, if used, to the skin smoothing effect and detected the differences in a more sensitive way. In the present study, abobotulinumtoxinA was reconstituted with 2.0 mL of sterile, preservative-free saline, while onabotulinumtoxinA was reconstituted with 2.4 mL of sterile, preservative-free saline. Anecdotal reports have surfaced of an increased risk of ptosis with abobotulinumtoxinA when used to treat the glabella. However, in the senior author's opinion, this is likely a complication directly resulting from the volume of reconstitution rather than the neuromodulator itself. Some clinicians have begun to use larger volumes (nearly 4 mL) of diluent in reconstituting abobotulinumtoxinA in order to use this product in a manner that is similar to how onabotulinumtoxinA is used. Such volumes would translate to larger volumes being used per aliquot, and as a result, more complications could ensue. A larger volume per aliquot would result in greater hydrostatic pressure, which could cause a greater risk of eyelid ptosis when treating the glabella. Furthermore, a larger volume per aliquot would cause a greater dispersion and diffusion of product, causing a greater risk of complications and a smaller dose being delivered at each injection focus. Thus, we recommend a 1.6-mL reconstitution of abobotulinumtoxinA.

CONCLUSION

In a double-blind, randomized, internally controlled study comparing onabotulinumtoxinA and abobotulinumtoxinA in the treatment of lateral orbital rhytids, abobotulinumtoxinA showed a statistically significant superiority in efficacy with a dosage ratio used for this study of 3 U of abobotulinumtoxinA to 1 U of onabotulinumtoxinA. In addition, by a 2-to-1 margin, patients chose the abobotulinumtoxinA-treated side of the face over the onabotulinumtoxinA-treated side. Such a comparative study should be used to assess efficacy for other facial muscle groups.

While trends were not statistically significant for line severity at rest, it did subjectively seem to the blinded evaluator and participants that in many patients the skin on one side appeared smoother than the other side. The inability to detect this difference using the 5-point validated Merz scale may indicate the scale's lack of refinement in measuring subjective differences in fine lines.

The data do not support superiority claims in other regions of the face or groups of facial muscles. Ongoing studies will determine whether the demonstrated patient preference and early advantage in clinical outcomes is persistent, as both the efficacy in line effacement and duration of effect are both important factors in patient and physician decision-making as it relates to the use of neuromodulators.

Accepted for Publication: March 15, 2011.

Published Online: June 20, 2011. doi:10.1001/archfacial.2011.37

Correspondence: Corey S. Maas, MD, The Maas Clinic, 2400 Clay St, San Francisco, CA 94115 (drmaas@maasclinic.com).

Author Contributions: Dr Maas, the principal investigator, and Dr Nettar had full access to all of the data in the study and take responsibility for the integrity of the

data and the accuracy of the data analysis. *Study concept and design*: Nettar, Bapna, and Maas. *Acquisition of data*: Nettar, Yu, and Maas. *Analysis and interpretation of data*: Nettar, Yu, Boscardin, and Maas. *Drafting of the manuscript*: Nettar, Yu, Bapna, and Maas. *Critical revision of the manuscript for important intellectual content*: Nettar, Boscardin, and Maas. *Statistical analysis*: Nettar, Boscardin, and Maas. *Obtained funding*: Bapna and Maas. *Administrative, technical, and material support*: Nettar, Yu, and Maas. *Study supervision*: Maas.

Financial Disclosure: Dr Maas is a consultant and owns stock in both Medicis Aesthetics Inc (makers of abobotulinumtoxinA) and Allergan Inc (makers of onabotulinumtoxinA).

Funding/Support: Funding for this study was solicited from both Medicis Aesthetics Inc and Allergan Inc. Medicis Aesthetics Inc funded this study.

Previous Presentation: This study was presented in part at the Fall Meeting of the American Academy of Facial Plastic and Reconstructive Surgery; September 24, 2010; Boston, Massachusetts.

REFERENCES

1. Maas CS. Botulinum neurotoxins and injectable fillers: minimally invasive management of the aging upper face. *Facial Plast Surg Clin North Am*. 2006;14(3):241-245.
2. Maas CS, Yu KCY, Egan KK. Neuromodulators and injectable soft tissue substitutes. In: Papel ID, ed. *Facial Plastic and Reconstructive Surgery*. 3rd ed. New York, NY: Thieme Medical Publishers; 2009:337-353.
3. Carruthers JD, Carruthers JA. Treatment of glabellar frown lines with *C. botulinum-A* exotoxin. *J Dermatol Surg Oncol*. 1992;18(1):17-21.
4. Bikhazi NB, Maas CS. Refinement in the rehabilitation of the paralyzed face using botulinum toxin. *Otolaryngol Head Neck Surg*. 1997;117(4):303-307.
5. Moy R, Maas C, Monheit G, Huber MB; Reloxin Investigational Group. Long-term safety and efficacy of a new botulinum toxin type A in treating glabellar lines. *Arch Facial Plast Surg*. 2009;11(2):77-83.
6. Carruthers A, Carruthers J, Hardas B, et al. A validated grading scale for crow's feet. *Dermatol Surg*. 2008;34(suppl 2):S173-S178.
7. Ascher B, Rzany BJ, Grover R. Efficacy and safety of botulinum toxin type A in the treatment of lateral crow's feet: double-blind, placebo-controlled, dose-ranging study. *Dermatol Surg*. 2009;35(10):1478-1486.
8. Monheit G, Carruthers A, Brandt F, Rand R. A randomized, double-blind, placebo-controlled study of botulinum toxin type A for the treatment of glabellar lines: determination of optimal dose. *Dermatol Surg*. 2007;33(1, special issue):S51-S59.
9. Pickett AM, Hambleton P. Dose standardisation of botulinum toxin. *Lancet*. 1994;344(8920):474-475.
10. Hambleton P, Pickett AM. Potency equivalence of botulinum toxin preparations. *J R Soc Med*. 1994;87(11):719.
11. Marion MH, Sheehy M, Sangla S, Soulayrol S. Dose standardisation of botulinum toxin. *J Neurol Neurosurg Psychiatry*. 1995;59(1):102-103.
12. Brin MF, Blitzer A. Botulinum toxin: dangerous terminology errors. *J R Soc Med*. 1993;86(8):493-494.
13. Marsden CD. The authors reply: botulinum toxin dangerous terminology errors. *J R Soc Med*. 1993;86(8):494.